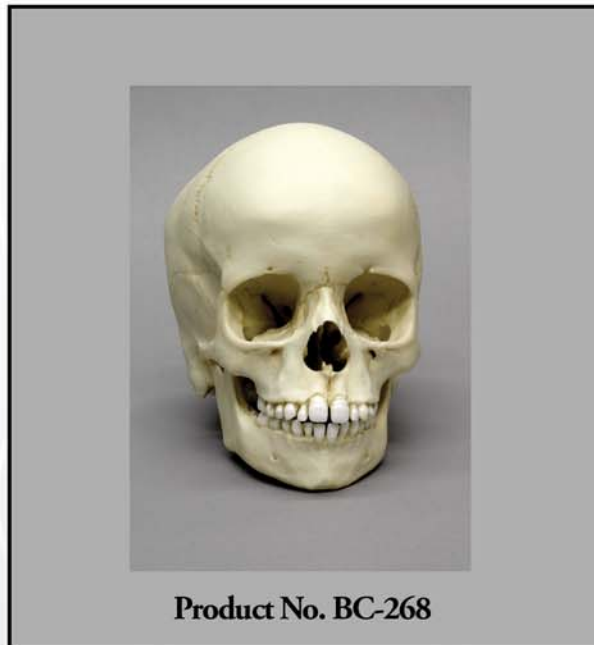


OSTEOLOGICAL EVALUATION

Prepared by
EVAN MATSHES BSc, MD
Consultant Osteologist



**Human 6-year-old
Child Skull
(6-7 years)**



Bone Clones, Inc.

OSTEOLOGICAL REPRODUCTIONS

9200 Eton Ave. Chatsworth, CA 91311

Phone: (818) 709-7991 or (800) 914-0091 (USA only)

Email: info@boneclones.com Web: www.boneclones.com

© Bone Clones, Inc. 2015

Human, Child (6-7 years)

Product Number: BC-268

Specimen Evaluated: Bone Clones® replica

Skeletal Inventory: 1 intact cranium
1 intact mandible

General observations:

In general, the molding process has preserved significant details necessary for evaluation. The general configuration of the skull is within normal limits. There is slight asymmetry to the skull with increased prominence of the right occiput. The general morphology of the individual visible cranial bones is within normal limits. Sutural patterns are of expected configuration. There is the (nasal) remnant of a partial metopic suture. There is a complete mendosal suture that traverses the squamous part of the occipital bone, dividing it into a tri-partate os-inca. The posterior intra-occipital sutures are fused. The anterior intra-occipital sutures are fusing. There are no sutural bones (Wormian ossicles). The foramina are of expected configuration. The skull is atraumatic.

There is an irregular exostosis at the anterior limb of the left occipital condyle; this is associated with asymmetry of the condyles (left larger than right).

Dentition:

There are 12 teeth in the maxillary arcade and 14 teeth in the mandibular arcade. There are mamelons on the maxillary and mandibular central incisors. There is slight shoveling of the maxillary central incisors.

The following fully erupted teeth are present in the maxillae: 1.6 [#3], 5.5 [A], 5.4 [B], 5.3 [C], 5.2 [D], 1.1 [#8], 2.1 [#9], 6.2 [G], 6.3 [H], 6.4 [I], 6.5 [J], and 2.6 [#14].

The following fully erupted teeth are present in the mandible: 3.6 [#19], 7.5 [K], 7.4 [L], 7.3 [M], 7.2 [N], 8.2 [Q], 8.3 [R], 8.4 [S], 8.5 [T], and 4.6 [#30].

The following empty gomphoses have features suggestive of early tooth calcification: 1.7 [2], 2.7 [#15], 3.7 [#18], and 4.7 [#31].

There are no dental restorations or prostheses. There is no significant attrition.

Non-Dental Features of Age:

Fontanelles

The anterior fontanelle is closed. The posterior, sphenoidal (anterolateral) and mastoidal (posterolateral) fontanelles are closed.

The spheno-occipital synchondrosis is open.

The calvarial sutures are all open (there is no evidence of ossification).

SUMMARY:

1. Age

Dental

Likely 6 - 7 years.

Non-Dental

Likely less than 10.5 years, greater than 1 year.

Anterior fontanelle closed.

Closure: median 13.8 months[1], range 4 – 26 months[2].

Posterior fontanelle closed.

Closure: 2 – 3 months[3].

Sphenoidal (anterolateral) fontanelle closed.

Closure: 2-3 months[3].

Mastoidal (posterolateral) fontanelle closed.

Closure: 1 year[3].

Spheno-occipital synchondrosis open.

Closure: 10.5 – 16 years[4, 5].

EDUCATIONAL RESOURCES:

1. This is an excellent example of a young child's skull.
2. It may be appropriate to discuss the differences between primary and secondary dentition, eruption patterns, and controversies surrounding the timelines that 'typify' those eruption patterns.
3. Age assessment of skeletal remains is best done in the context of the entire skeleton. It is important for educators to emphasize that when limited to the skull, age assessment of subadult remains is best done through a coordinated evaluation of such features as dentition and fontanelle closure, as well as radiographs and/or computed tomography (CT) scans. This is particularly key for studies of tooth development (calcification, eruption). It is important to emphasize that the evaluation of a skull without these methods is artificial, and not reflective of actual practice. However, the ability to analyze such remains from the strict perspective of osteology is fundamental, and students must feel comfortable analyzing subadult skulls and skeletons.
4. It is not currently possible to reliably differentiate amongst the major racial groups within subadults.[6]
5. It is not currently possible to reliably differentiate male and female infant and young child skeletal remains.[6]
6. In the evaluation of subadult skulls, particularly when studying 'typical' eruption patterns, students must be cautioned that statistical data is based on **populations**, and may not necessarily be reflective of reality in an **individual**.
7. It may be appropriate to discuss the concept of sutural (Wormian) bones and what role they may play in the forensic evaluation of cranial remains. It is most important that students understand sutural bones are normal variants which may be present with somewhat increased frequency in some racial groups; they must not be misdiagnosed as fractures.
8. This is an excellent example of a persistent mendosal suture; it is important that students are aware of this normal variant, and that it is not misdiagnosed as a fracture.

Bone Clones® Osteological Evaluation Report

REFERENCES:

1. Kiesler, J. and Ricer, R. (2003). The abnormal fontanel. *American Family Physician*, 67(12): 2547-52.
2. Tunnessen, W.W., Jr. (1990). Persistent open anterior fontanelle. *JAMA*, 264(18): 2450.
3. Standring, S., Ed. (2005). *Gray's Anatomy: The Anatomical Basis of Clinical Practice*. 39 ed. London: Elsevier (Churchill Livingstone).
4. Konie, J. (1964). Comparative value of X-rays of the spheno-occipital synchondrosis and of the wrist for skeletal age assessment. *The Angle Orthodontist*, 34(4): 303-313.
5. Powell, T.V. and Brodie, A.G. (1963). Closure of the Spheno-Occipital Synchondrosis. *Anatomical Record*, 147: 15-23.
6. Matshes, E. and Lew, E. (2006). Forensic osteology. In *Forensic Pathology: Principles and Practice*, D. Dolinak, E. Matshes, and E. Lew, Editors. San Diego, CA: Elsevier (Academic Press).

DISCLAIMERS:

This report is meant only as a teaching tool for introductory level students of the anatomical, anthropology or forensic sciences who might be using this specimen to learn human and forensic osteology. Evaluation of osteologic material is best done with original specimens. My evaluation was based solely upon studies of a Bone Clones® replica. My opinions are based solely upon the material presented to me. This is somewhat artificial as in real forensic investigations additional studies would be undertaken prior to the formulation of diagnoses and the production of a report. These studies might include plain film radiography, computed tomography (CT) studies, histology, etc. Evaluation of a child skull for age always involves radiography. Osteologic/odontologic evaluation of age based purely on visible eruption patterns is a useful basic skill, but is artificial and not representative of actual practice. My opinions regarding this skull were made without access to the postcranial skeleton.

Evan Matshes BSc, MD
Consultant Osteologist