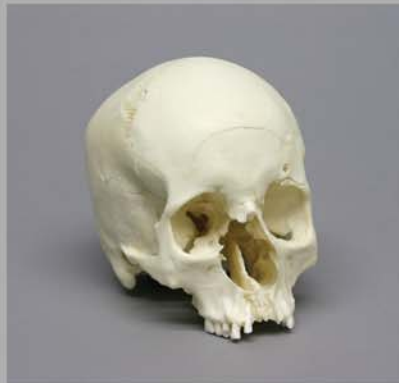

OSTEOLOGICAL EVALUATION

Prepared by
Karen Ramey Burns, Ph.D.
Forensic Anthropologist



Product No. BCM-805

Blunt Force Trauma, Eye Orbit



Bone Clones, Inc.

OSTEOLOGICAL REPRODUCTIONS

9200 Eton Ave. Chatsworth, CA 91311

Phone: (818) 709-7991 or (800) 914-0091 (USA only)

Email: info@boneclones.com Web: www.boneclones.com

Human Skull Blunt Force Trauma, Eye Orbit

Product Number: BCM-805

Maxwell Museum of Anthropology:

The Maxwell Museum of Anthropology's Laboratory of Human Osteology, at the University of New Mexico, specializes in numerous facets of physical anthropology. The laboratory serves as a repository of human remains and includes prehistoric, historic, documented, and forensic remains.

Established in 1984 by Dr. J. Stanley Rhine, the Maxwell Museum's Documented Skeletal Collection has grown to include 237 individuals (as of July 2005) encompassing both sexes, all ages, and many population groups. The skeletal remains are obtained by donation, either by the individual before death, or by the family of a deceased loved one. Information on the sex, age, population affinity, and cause of death is available for the majority of these individuals, allowing students and visiting researchers to develop and test new techniques and theories.

Since 1995, prospective donors or their families have been asked to provide health and occupational data as well. With this information, researchers are able to examine the skeletal manifestations of particular diseases including degenerative joint and disc diseases, lymphoma, and osteoporosis, as well as the reaction of bone to repetitive motions and trauma. Recent research has included efforts towards the identification of handedness in individuals, determination of body mass from the skeleton, and variation in cranial damage from various projectiles. The importance of the Documented Collection cannot be overstated. No other institution in the American West has as large a collection of human skeletal remains with such extensive demographic data.

Bone Clones is grateful to the Maxwell Museum for allowing us to select specimens for reproduction from their valuable collection and granting us exclusive casting rights to these pieces.

Human Skull Blunt Force Trauma, Eye Orbit

Product Number: BCM-805

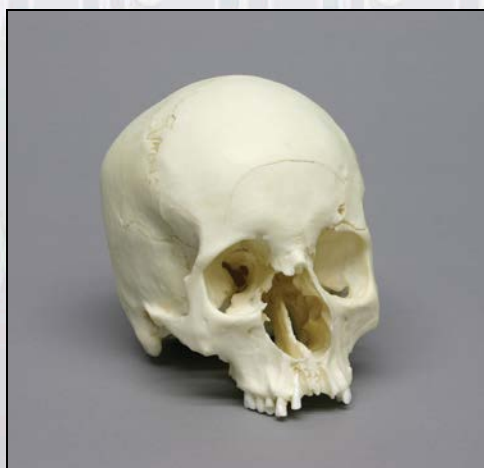
Specimen Evaluated: Bone Clones® Cast of cranium (no mandible)

Skeletal Inventory: 1 cranium with partial dentition

Osteological Observations:

This is the cranium of a modern human female with perimortem facial fractures caused by a blunt instrument. The major impact occurred on the left supraorbital margin. The fractures extend into the left orbit, across the forehead, through the bridge of the nose, and into the right orbit. A secondary impact occurred above the left ear.

Figure 1:



Dentition: Nine of the original 16 teeth remain in the maxilla (##1, 3-7,11-13).

The dentition was complete at the time of death. In other words, all 16 adult teeth were present in the maxilla. Seven teeth were lost after death (##2, 8-10, 14-16). The tooth sockets (alveoli) are open and show no signs of healing. The third molar (#1) appears to have been in the process of erupting at the time of death. The full crown of the molar is visible, but the cusps have not reached the plane of occlusion.

There is no perceptible tooth wear, but several of the teeth (## 5, 6, 11, 13) are broken in a manner consistent with postmortem cracking. This typically happens when teeth are exposed for a long period of time to a dry environment. The broken surfaces are flat, edges are straight, and corners are sharp.

The nasal spine and the labial plate of the maxillary alveolar ridge is broken off, and the roots of incisors ## 7-9 are exposed. This break may have occurred coincidentally with the trauma to the orbit and nose. If so, the nose itself was probably smashed.

Features of Race:

This individual displays racial characteristics that could indicate European and/or Asian origins. The face is narrow with delicate zygomas and a high, smooth forehead. (The zygomas alone suggest European origin, not Asian.) The nasal aperture is narrow (total width was estimated from the unbroken half), and the nasal sill is sharp. The nasal spine is broken and the original size is not determinable. The palate is narrow and parabolic in shape. (All of these factors exclude West African or American Indian origin.) The teeth are relatively small. There is no Carabelli's cusp (a European trait) on the one remaining first molar, and the form of the incisors cannot be assessed because only one broken lateral incisor is present.

Analysis of cranial measurements by Fordisc 3.0 results in classification as "Japanese female," with a posterior probability of 0.980 when compared with European, African, and American Indian female populations. This is not enough information with which to confirm racial identity, but it provides interesting clues.

Features of Sex:

This is a typical female cranium. The forehead is smoothly curved without frontal bossing, and the supraorbital margins are sharp. The mastoid processes are relatively small, and there is no suprameatal crest. The nuchal area of the occipital is relatively smooth and devoid of ridges, and there is no nuchal protuberance.

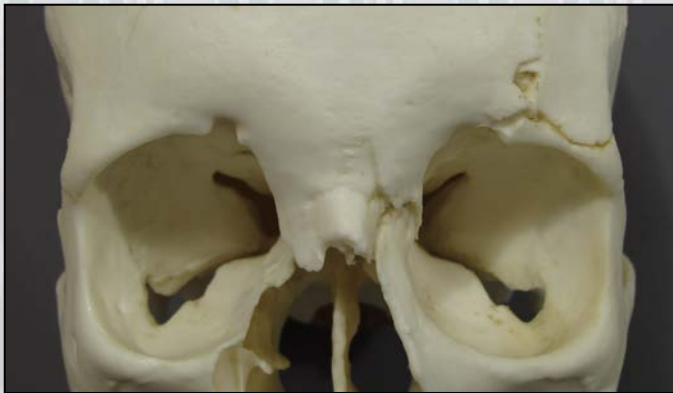

Figure 2: Frontal View of Orbits

Note the smooth feminine brow ridge, and the sharp supraorbital margins. The central part of the forehead is elevated, i.e. there is no double bossing. The supraorbital margins and frontal bossing can be evaluated by touch when compared with a known male skull.

Figure 3: Posterior View of Occipital

Note the relatively smooth external occipital protuberance (arrow). The attachment site for the medial nuchal ligament is insignificant when compared to individuals (usually male) with heavy neck musculature.



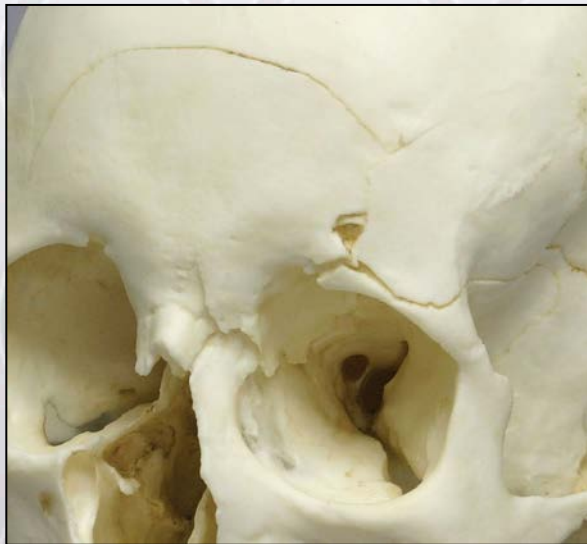Features of Age:

Based on the limited information provided, this appears to be a young adult. The basioccipital suture (or synchondrosis) is fused, but all major cranial sutures are patent. The one remaining third molar is partially erupted, but not in occlusion.

Evidence of Trauma:

This person sustained a blunt-force type of injury to the face near the time of death. The fractures could have resulted from a variety of mechanisms, e.g., a forceful blow from an instrument such as baseball bat or an impact with a steering wheel in a vehicular accident. The injury was not caused by a sharp instrument such as a knife or by a bullet.

Figure 4: Frontal Bone and Left Orbit



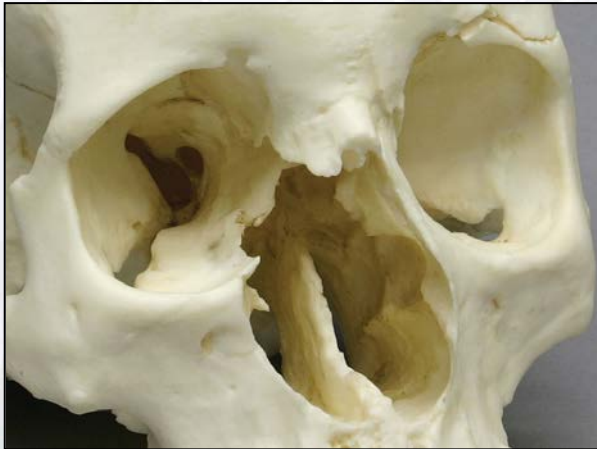One impact point is on the left supraorbital margin. A fracture proceeds superiorly and another fracture branches off and arcs across the anterior portion of the frontal to just above the right supraorbital margin. The arcing fracture is a typical “concentric fracture” caused by bending (plastic deformation) of the bone around the point of impact.

Another fracture extends laterally from the point of impact along the supraorbital margin and stops at the sphenoid suture. (Fractures typically terminate at sutures or at prior fracture lines.)

A third fracture extends posteriorly through the orbital roof then curves medially to end at the ethmoid suture. The orbital portion of the frontal bone is levered over the lateral plate of the ethmoid.

In addition, the left greater wing of the sphenoid was pushed under the left temporal, creating a break in both the sphenoid and the adjacent temporal bone. A secondary blow above the left external auditory meatus contributes to the temporal fracture pattern. (See Figure 6.)

Figure 5: Left Medial Orbital Wall and Nasal Bones



The frontal process of the right maxilla is broken off and missing together with the right lacrimal, part of the right lateral wall of the ethmoid, and the nasal conchae. The nasal bones are broken off at 8 mm. below nasion (the bridge of the nose). Another fracture line extends posteriorly on the orbital roof.

There is one more small fracture on the frontal bone near the right side of the coronal suture. It is not obvious whether or not this fracture is associated with any of the others.

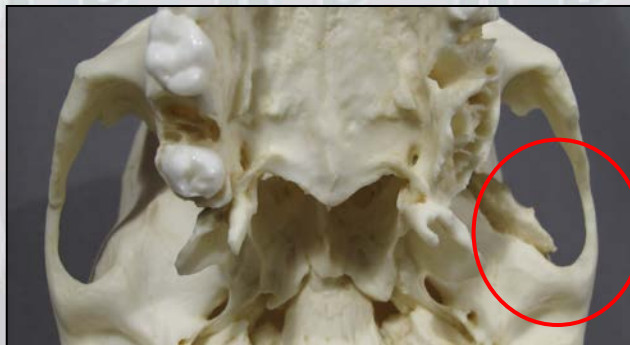

Figure 6: Basilar View of Cranium and Temporal Bone Trauma

Compare the circled area on the left side of the skull with the opposite side. The temporal bone is split away from the sphenoid, in association with blunt force trauma immediately above the root of the zygomatic process of the temporal.

SUMMARY:

1. Race: Undetermined.
2. Sex: Female.
3. Age: Young adult.
4. Trauma: Major blunt force trauma to the nose, left eye orbit, and left ear with peripheral damage to the entire face.

Educational Resources:

1. This skull is an excellent example of the expanding and permeating skeletal effects of blunt force injury to the face.
2. Educators may want to use this skull as a launching point for a discussion of the mechanisms of maxillofacial and cranial trauma. Velocity of impact, shape of weapon, bone strength and elasticity, and LeForte fracture classification, can all be addressed.
3. The skull itself can lead to a discussion of physical symptoms in the living person. For example, “If the blow was to the left eyebrow, why is the person having difficult breathing, seeing, chewing, or hearing?”
4. Educators may want to use this skull together with other skulls that have sustained different types of trauma, e.g. gunshot, machete, surgical tools, and vehicular. The comparison will serve to highlight the effects of types of “weapons” and velocity of impact.
5. This skull can also be used as an example of a female skull with mixed racial traits.

References:

Berryman, H.E., & Symes, S.A. (1998). Recognizing Gunshot and Blunt Cranial Trauma Through Fracture Interpretation. In K.J. Reichs (Ed.) *Forensic Osteology* (2nd ed.), (pp. 333-352). Springfield, IL: CC Thomas.

Ousley, S.D., & R.L. Jantz (2005). *FORDISC 3.0: Personal Computer Forensic Discriminant Functions*. University of Tennessee.

Seyfer A.E., & Hansen, J.E. (2003). Facial trauma. In E.E. Moore, D.V. Feliciano, K.L. Mattox (Eds.) *Trauma* (5th ed.), (pp. 415-436). McGraw-Hill Professional.

Stewart. M.G. (2005). *Head, Face, and Neck Trauma: Comprehensive Management*, New York: Thieme.

Thaller SR. (2004). *Facial Trauma*. New York: Marcel Dekker.

Disclaimers:

This report is meant as a teaching tool for introductory level students of the anatomy, anthropology or forensic sciences who may be using this specimen to learn human and forensic osteology. My opinions are based solely upon the material presented to me. This is somewhat artificial as in real forensic investigations additional studies would be undertaken prior to the formulation of diagnoses and the production of a report. These studies might include plain film radiography, computed tomography (CT), histology, etc. My opinions regarding race and sex are based upon both metric and non-metric analysis and without access to the postcranial skeleton.

Karen Ramey Burns, Ph.D.
Forensic Anthropologist