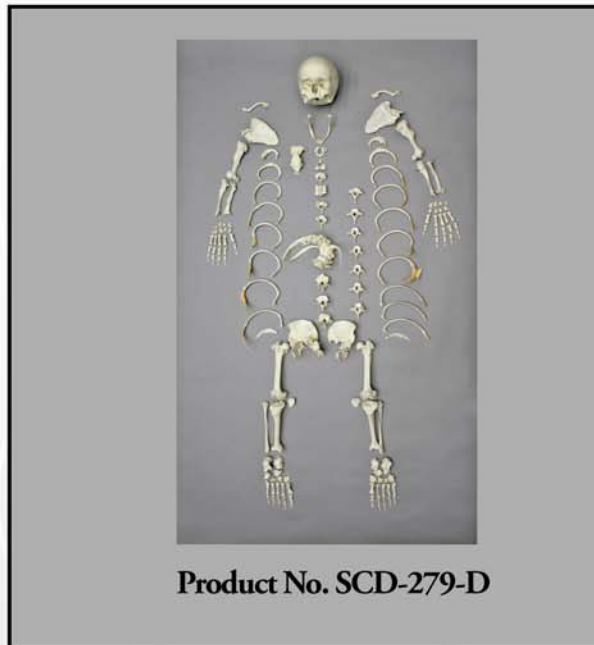


OSTEOLOGICAL EVALUATION

Prepared by
Karen Ramey Burns, Ph.D.
Forensic Anthropologist



Human Female Achondroplasia Dwarf Disarticulated Skeleton



Bone Clones, Inc.

OSTEOLOGICAL REPRODUCTIONS

9200 Eton Ave. Chatsworth, CA 91311

Phone: (818) 709-7991 or (800) 914-0091 (USA only)

Email: info@boneclones.com Web: www.boneclones.com

© Bone Clones, Inc. 2015

Human Female Dwarf Skeleton, Achondroplasia

Product Number: SCD-279

Specimen Evaluated: Original Specimen

Skeletal Inventory:

- One intact cranium
- One intact mandible
- One complete postcranial skeleton

General Osteological Observations:

This complete skeleton demonstrates the classic features of achondroplasia dwarfism and reveals pathological modifications that are common consequences of the condition. The most obvious features are short stature (less than 4'10" adult height) and a large head. The limbs are proportionally shorter than the trunk. The mid-back has a sharp forward bend (kyphosis) and the curvature of the lower back is exaggerated.

Skull:

The neurocranium is large in relation to the face. The forehead bulges and double bossing is visible on the frontal bone (See Figure 1). The nasal bridge is depressed, the nasal spine is large and the nasal bones appear constricted, bending sharply and jutting outward (See Figure 2).

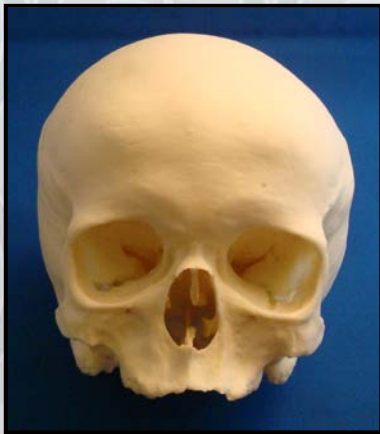


Figure 1: Frontal View of Cranium

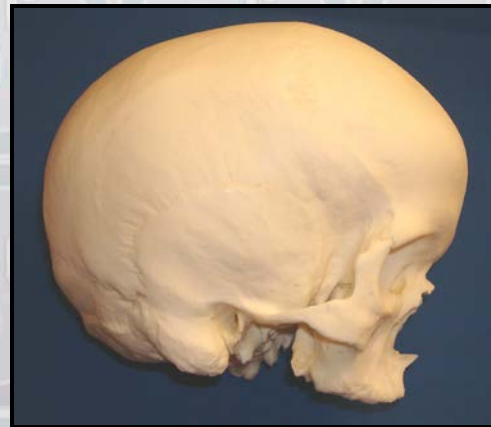
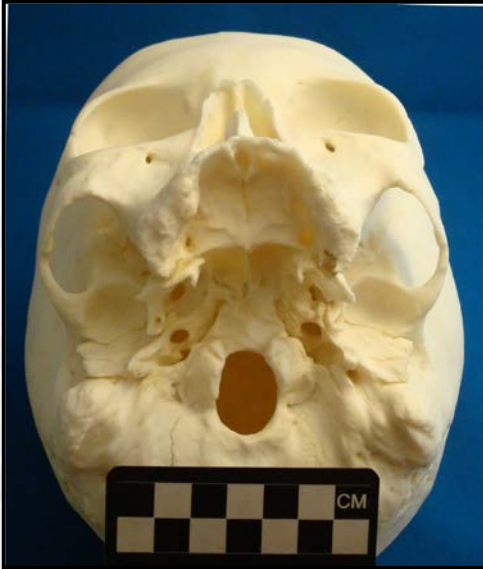
Figure 2: Lateral View of Cranium

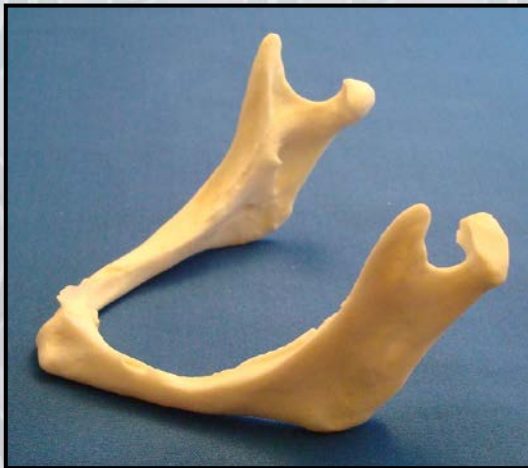

The foramen magnum is extremely small, a condition known as *foramen magnum stenosis* (See **Figure 3**). The condition carries a number of clinical consequences, including serious nerve compression.

Figure 3: Foramen Magnum Stenosis

Dentition:

The individual was completely edentulous at the time of death (See **Figure 4**). All dental alveoli are healed and the surrounding bone is greatly resorbed. On both the maxilla and mandible, the labial portion of the alveolar ridge is sharp, and the buccal portion is thick and rounded. The mandibular height is less than 1 centimeter, and the mandible is so reduced that the superior surface of the alveolar ridge encroaches upon the mental foramina.



Dental crowding is reported as a condition of achondroplasia. The complete loss of teeth in this individual may have been secondary to dental crowding and malalignment. The shape of the mandibular condyles is modified. This is a typical result of total tooth loss and the subsequent realignment of the maxilla and mandible.

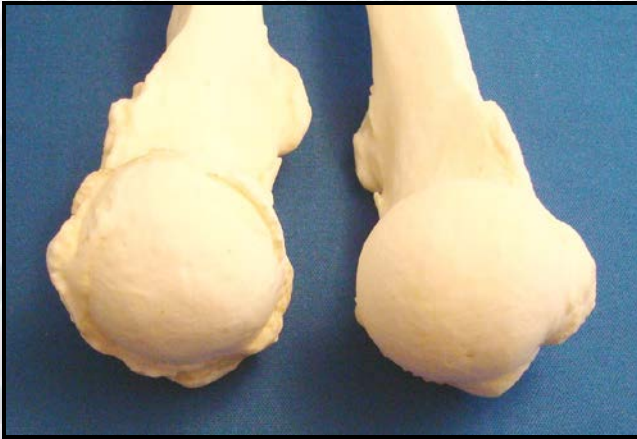Figure 4: Edentulous Jaw: The alveolar ridges are healed and severely reduced following long-term tooth loss. The mandibular height is less than 1 cm.

Upper Limbs:

The arms are short in relation to the length of the trunk of the body, and the proximal segments of the arms are relatively shorter than the more distal segments, a condition known as *rhizomelic micromelia*. In other words, the humerus (upper arm bone) is even more reduced in size relative to normal than are the radius and ulna (forearm). The metacarpals (bones of the palm) are also abnormally short, but the phalanges (finger bones) are near-normal in size.

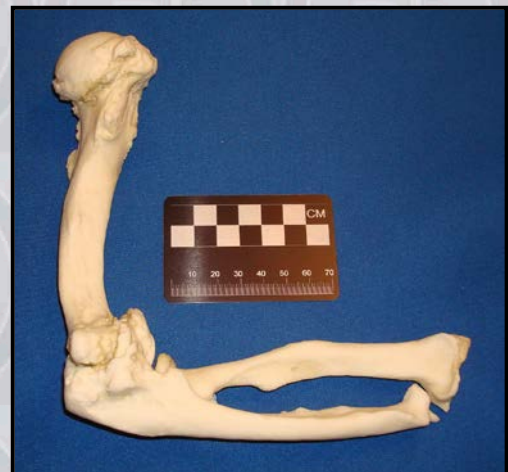Both humeri show pronounced torsion and arthritic modifications, but the left humerus is more deformed than the right (See **Figure 5**). The deltoid tuberosities of the humeri are very large and prominent, suggesting well-developed shoulder muscles. The radial tuberosities are large in relation to the size of the radius, suggesting relatively large biceps muscles.

Figure 5: Right and Left Humeral Heads



The elbow joints are extremely arthritic (See **Figure 6**). The capitulum of the left humerus is eburnated from the effects of bone-on-bone articulation between the humerus and radius, and the movement of the ulnae on the troclea of the humeri is severely limited. Extension is not possible beyond 90 degrees, making the arms permanently bent. (Complete extension would be 180 degrees.)

Figure 6: Reduction of Elbow Extension: The elbows are permanently flexed. Neither one extends much beyond a 90 degree angle to the humerus. This is due to buildup of osteophytic bone and closure of the olecranon fossa of the humerus.



Thorax:

The manubrium, sternal body and xiphoid process are all fused together, and the sternum as a whole has an abnormally strong anterior curvature.

Portions of the vertebral column are fused, and the rib cage is misshapen (See Figure 7). An entire section of vertebral bodies in the center of the back (T8-L2) are collapsed and fused (*ankylosed*) into a solid mass which includes the vertebral arches. The fused area is sharply bent, resulting in a permanently humped back or *kyphosis*. (This is also called a *gibbus deformity*.)

Within the fused section of vertebrae, three ribs are fused to the vertebral mass. The right tenth rib is missing, possibly due to its delicate condition at the time of death. Large syndesmophytes (bony growth within ligaments) are found attached to the inferior border of the ninth rib and may indicate the remains of a fractured and mostly-resorbed tenth rib.

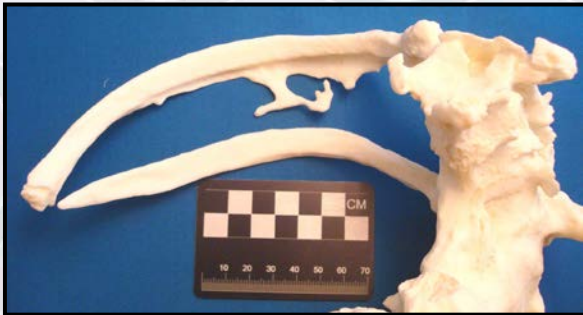

Figure 7: Kyphosis and Fusion: Seven vertebrae in the center of the back (T8-L2) are fused into a solid bony mass, producing a permanent hump back deformity (*kyphosis*). Three ribs are fused to the vertebral mass.

Pelvis

The abnormal shape of the sacroiliac joint between the pelvic girdle and the sacrum produces a pronounced and permanent sway of the lower back (*lordosis*). In the living person, this bony configuration results in prominent buttocks and a protuberant abdomen.

The innominate (*os coxae*) is small and female in form. The pubis is mediolaterally elongated and the sub-pubic angle is wide. A clearly-defined ventral arc is present. (See Figure 8)

The sacrum is fused to the right innominate (but not the left) and is unusually flat. The auricular surfaces of the sacrum are greatly reduced and sharply curved. The superior surface of S1 is decidedly angled, resulting in an extreme anterior projection of the sacral promontory (See Figure 9).

Figure 8: Female Pubis

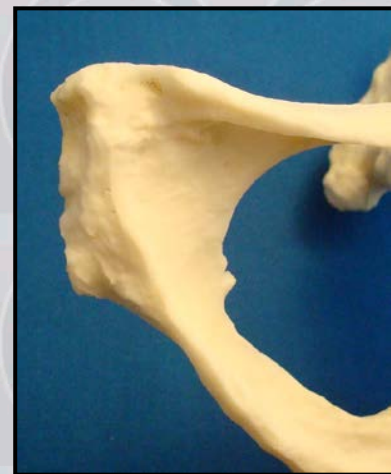
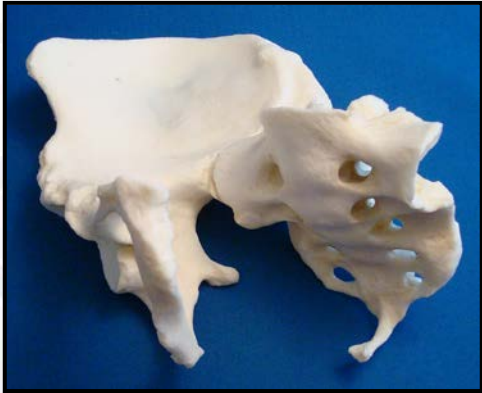
Figure 9: Flat Sacrum and Sharply Curved Coccyx



The coccygeal bones are fused to each other and to the sacrum. They are sharply curved anteriorly and would have impinged upon the pelvic floor during life (See Figure 9).

Lower Limbs

The leg bones are short in relation to the length of the trunk of the body. The left tibia and fibula are fused, possibly a result of trauma to the limb. All of the leg bones are extremely osteoporotic.

The medial and distal phalanges of both fifth toes are fused.

Features of Race:

It is not possible to scientifically analyze race in this specimen due to lack of known-race comparative material for dwarfs. (For general interest, it is noted here that achondroplasia is not race-specific. The condition is said to occur in 1 in 15,000 to 40,000 newborns, regardless of race.)

Features of Sex:

In spite of its small size, the pelvis demonstrates the classic characteristics of a female genotype. The pubis is elongated and the sub-pubic angle is wide. The ventral arc is obvious.

Features of Age:

The age at death is known to be around 60, and the overall skeletal age is consistent with that of a person beyond middle age. The diseases of the elderly are all present: the synovial joints are arthritic (e.g., shoulders, elbows, knees); the cartilaginous joints have degenerated (e.g., pubic symphysis, auricular surface of the ilium, vertebral body surfaces); the costal cartilage has begun to ossify; the vertebral bodies are fringed with osteophytes and compression fractures are present; the maxilla and mandible are edentulous.

Evidence of Disease (Pathology):

The skeletal modifications of achondroplasia are all present as well as severe arthritis and other age-related diseases. The following is a check list of conditions.

1. gibbus deformity or structural kyphosis (hunch back) with fusion of T8-S2 and adjacent ribs
2. lordosis, visible in the angle of the L5-S1 articulation and the flat, posteriorly-jutting sacrum
3. foramen magnum stenosis (small opening for passage of spinal cord into skull)
4. generalized osteoarthritis
5. elbow joint extension confined to 90 degrees
6. fusion of left tibia and fibula, C4 and C5, the right innominate with sacrum, the coccyx, and the medial and distal phalanges of the fifth toes on both feet.
7. syndesmophytes (bony growths inside of ligaments) on 9th right rib
8. anterior curvature of sternal body
9. severe osteoporosis of the lower limbs
10. complete tooth loss (edentulous)

Evidence of Trauma:

There is no obvious evidence of antemortem or perimortem trauma. In other words, there is no evidence of bone fractures, blunt-force trauma, sharp-force trauma (knife wounds), or gunshot wounds.

There is, however, ample evidence of stress-related trauma to the left shoulder. The glenoid fossa of the left scapula and the head of the left humerus are far more arthritic than the right. In addition, the capitulum of the distal humerus is eburnated, i.e., the articular cartilage was lost during life and the head of the radius articulated with the distal humerus directly without the benefit of a synovial joint. (The resulting bony surface is very dense, smooth, and shiny.) This may possibly be related to left-handedness.

There is also evidence of wheelchair use. The bone of the upper limbs is much denser than that of the lower limbs, and the deltoid and radial tuberosities of upper limbs are extremely robust. This can be associated with increased use of the upper limbs and very little use of the lower limbs. In addition, the ischial tuberosities of the pelvis are virtually flattened, particularly on the right side. This may be attributed to bone resorption secondary to decubitus ulcers (pressure sores) common among wheelchair users.

SUMMARY:

Race: Undetermined, although the nasal form is consistent with European origin.
Sex: Reported to be female. The pelvic form, particularly the pubis, support that information.
Age: Reported to be around 60. The skeletal evidence does not contradict that information. The remains appear to be middle aged or older, based on generalized degenerative changes in all joints.
Pathology: Achondroplasia and associated skeletal modifications
Trauma: No perimortem trauma is visible. Antemortem trauma can be attributed to aging and achondroplasia.

Bone Clones*® *Osteological Evaluation Report

Educational Resource Suggestions:

1. This is an excellent skeleton to demonstrate the bony effects of achondroplasia and discuss the genetics of the disease.
2. Educators may want to use this skeleton as a launching point for the discussion of endochondral bone formation, and the mechanism for calcification of cartilaginous models in long bone growth.
3. This skeleton also provides an opportunity to discuss the plasticity of bone under stress. For example, note the effects of wheelchair use on the density and configuration of upper limbs in comparison to lower limbs.
4. This skeleton can also be used to test the students' ability to distinguish human from non-human remains. The clavicles, for instance, are very different from normal clavicles, but they are still recognizably human.

References:

Defendi, G. (August 2009) *Achondroplasia*, eMedicine's clinical reference, located at <http://emedicine.medscape.com/article/941280-overview>

Hecht, J.T., Horton, W.A., Reid, C.S., Pyeritz, R.E., Chakraborty, R., (1995). Growth of the foramen magnum in achondroplasia. *American Journal of Medical Genetics*, **32**(4):528 – 535

Richette, P, Bardin, T, Stheneur, C. (2008) Achondroplasia: from genotype to phenotype *Joint Bone Spine*, **75**(2): 125-30.

Disclaimers:

This report is meant only as a teaching tool for introductory level students of the anatomical, anthropology or forensic sciences who might be using this specimen to learn human and forensic osteology. My opinions are based solely upon the material presented to me. This is somewhat artificial as in real forensic investigations additional studies would be undertaken prior to the formulation of diagnoses and the production of a report. These studies might include plain film radiography, computed tomography (CT) studies, histological analysis, etc. My opinions regarding race and sex are based only upon non-metric analyses.

Karen Ramey Burns, Ph.D.
Forensic Anthropologist