


# OSTEOLOGICAL EVALUATION

*Prepared by*  
**Tori D. Randall, Ph.D.**  
Biological Anthropologist



## Human Female European Articulated Skeleton



**Bone Clones, Inc.**

OSTEOLOGICAL REPRODUCTIONS

9200 Eton Ave. Chatsworth, CA 91311

Phone: (818) 709-7991 or (800) 914-0091 (USA only)

Email: [info@boneclones.com](mailto:info@boneclones.com) Web: [www.boneclones.com](http://www.boneclones.com)

© Bone Clones, Inc. 2015

# **Human Female European Articulated Skeleton**

**Product Number:** SCM-191

## **Known Information:**

All bones are associated in this skeleton of a documented 41-year-old European female, who stood 5'6" and weighed 133 pounds at time of death. Cause of death was heart failure due to drug overdose. Information about this individual was documented at the time of her death.

## **Maxwell Museum of Anthropology:**

The Maxwell Museum of Anthropology's Laboratory of Human Osteology, at the University of New Mexico, specializes in numerous facets of physical anthropology. The laboratory serves as a repository of human remains and includes prehistoric, historic, documented, and forensic remains.

Established in 1984 by Dr. J. Stanley Rhine, the Maxwell Museum's Documented Skeletal Collection has grown to include 237 individuals (as of July 2005) encompassing both sexes, all ages, and many population groups. The skeletal remains are obtained by donation, either by the individual before death, or by the family of a deceased loved one. Information on the sex, age, population affinity, and cause of death is available for the majority of these individuals, allowing students and visiting researchers to develop and test new techniques and theories.

Since 1995, prospective donors or their families have been asked to provide health and occupational data as well. With this information, researchers are able to examine the skeletal manifestations of particular diseases including degenerative joint and disc diseases, lymphoma, and osteoporosis, as well as the reaction of bone to repetitive motions and trauma. Recent research has included efforts towards the identification of handedness in individuals, determination of body mass from the skeleton, and variation in cranial damage from various projectiles. The importance of the Documented Collection cannot be overstated. No other institution in the American West has as large a collection of human skeletal remains with such extensive demographic data.

Bone Clones is grateful to the Maxwell Museum for allowing us to select specimens for reproduction from their valuable collection and granting us exclusive casting rights to these pieces.

# **Human Female European Disarticulated Skeleton**

Product Number: SCM-191

Specimen Evaluated: Bone Clones® replica

Skeletal Inventory: Complete skeleton

## Osteological Observations:

This is a complete adult human skeleton with 28 teeth. Since there are no duplicate skeletal elements, and the bones from the right and left side of the body are consistent in size and shape, it is possible to conclude that there is only one individual represented.

## Dentition:

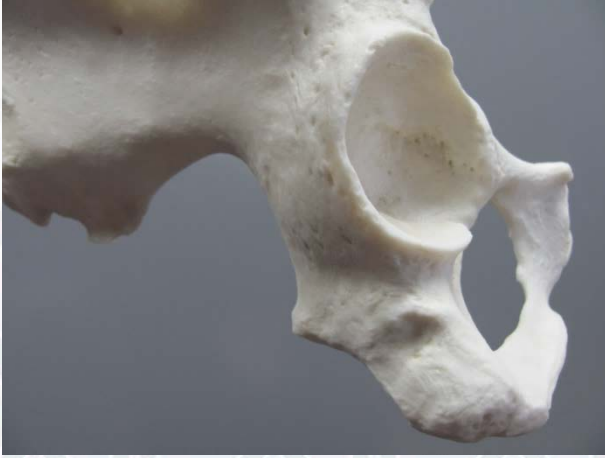The skull exhibits full adult dentition with the exception of all of the 3<sup>rd</sup> molars. There is no evidence of carious lesions, dental abscessing, or excessive dental attrition.

## Features of Sex:

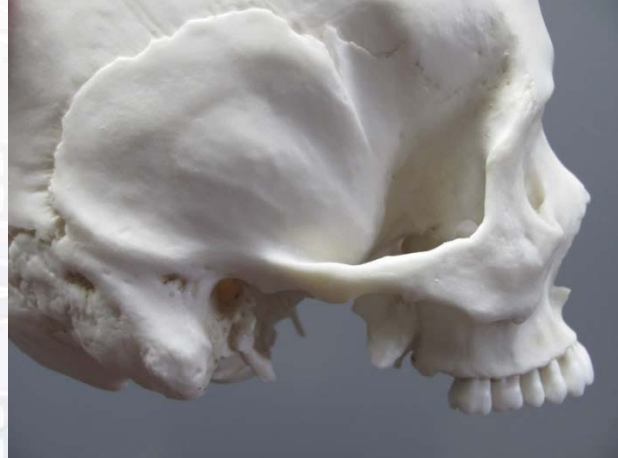The features of the pelvis are typical of a female. Determination of sex was made by visually scoring a variety of sexually dimorphic skeletal criteria. Morphological features of the pelvis such as a ventral arc, subpubic concavity, ischiopubic ramus ridge, and parturition pits were all present, which suggests that this is a female (Phenice, 1969). The total pelvis shape is wide and broad, the pelvic outlet is large, and the greater sciatic notch, as well as the subpubic angle, are wide (Buikstra and Ubelaker, 1994; White and Folkens, 2000). All of these traits are consistent with female morphology.

Females tend to have smaller, slighter skulls than males. In this case, the morphology of the skull is consistent with that of the female sex. Various cranial characteristics were evaluated; such as the small mastoid processes, a sharp supraorbital margin, and the pointed mental eminence on the mandible (Buikstra and Ubelaker, 1994; Bass, 1995; White and Folkens, 2000).





*Figure 1: The greater sciatic notch is wide, which is indicative of females.*



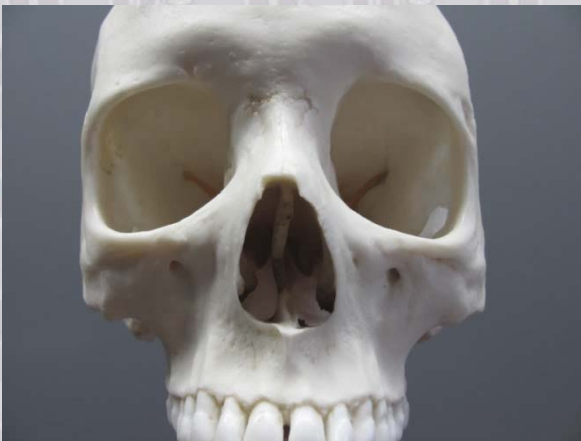*Figure 2: The mastoid process is small, which is often the case in female skulls.*

**Features of Age:**

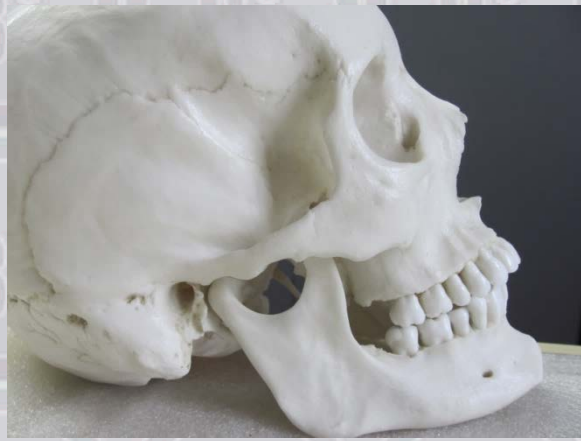Since all of the permanent dentition was present, and epiphyseal union was complete, the skeleton was classified as an adult. It is also evident that very few degenerative changes have begun; therefore, this is not an elderly individual. Criteria such as the morphology of the pubic symphysis and cranial suture closure were used to estimate age. Pubic symphyseal change is one of the most reliable criteria for estimating age at death in adult skeletal remains. This trait was scored for age using the Suchey-Brooks method (Brooks and Suchey, 1990), with a resulting phase 4 determination. The degree of cranial suture closure was also used, even though there is considerable variability in closure rates (Meindl and Lovejoy, 1989). The skeletal morphology is consistent with a middle aged adult (35-45 years).

**Features of Ancestry:**

A variety of morphological traits of the skull were used to determine the European ancestry of this individual. For example, the nasal aperture is narrow/vertical, and there is poor dental occlusion (overbite), which are all morphological traits indicative of Europeans.



*Figure 3: Narrow nasal aperture, which is indicative of European ancestry.*



*Figure 4: Poor dental occlusion indicates European descent.*

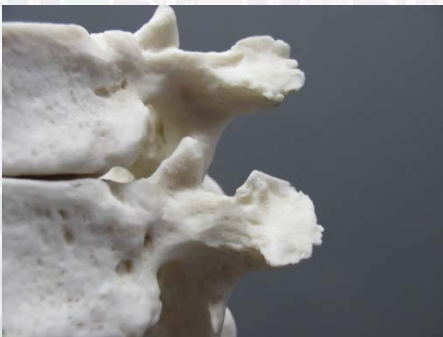## ***Bone Clones® Osteological Evaluation Report***

### Stature Estimation:

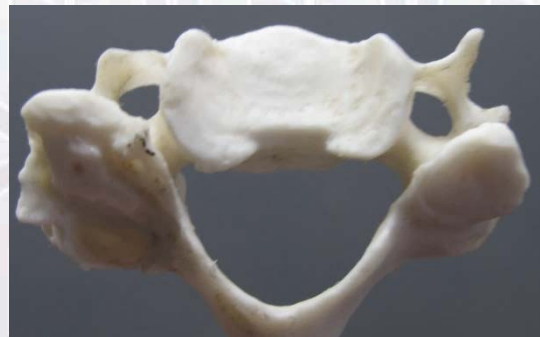Since all of the skeletal elements are present, the revised Fully stature estimation technique was used in this case (Raxter et al., 2006), and resulted in a stature estimation of 159.81 cm +/- 4.5 cm.

### Trauma and Pathology:

There is no evidence of trauma. There is osteophyte development on the left transverse processes of T9 and T10, as well as on the left superior and inferior articular facets of C4 and C5.



*Figure 5: 9<sup>th</sup> and 10<sup>th</sup> thoracic vertebrae.*



*Figure 6: 4<sup>th</sup> cervical vertebra.*

### SUMMARY:

1. Sex: Female
2. Age: Middle aged adult (mid-30s to mid-40s)
3. Ancestry: European
4. Stature: 155.31 cm – 164.31 cm
5. Trauma/Pathology: Slight osteophyte development on multiple vertebrae.

### Educational Resources:

1. This is an excellent example of an adult female skeleton.
2. All of the developmental skeletal changes are complete, but very few degenerative changes have begun. This makes this skeleton a good candidate for discussing and observing morphological traits in middle-aged adults.
3. Since all of the skeletal elements are present, this is a good skeleton to use when discussing the importance of looking at the entire skeleton when assessing sex, age, and ancestry. For example, even though the pelvis is the most reliable indicator of sex, it is still important to look at other aspects of the skeleton, such as the skull. Furthermore, this skull displays some evidence of Asian traits, such as wormian bones, in addition to traits which are indicative of European



## ***Bone Clones® Osteological Evaluation Report***

ancestry. This makes this skeleton a good example for discussing the inter-mixing of ancestral groups.

### References:

Bass WM. 1995. *Human osteology: A laboratory and field manual of the human skeleton*. Columbia: Missouri Archaeological Society.

Brooks ST, Suchey JM. 1990. Skeletal age determination based on the os pubis: A comparison of the Acsádi-Nemeskéri and Suchey-Brooks methods. *Human Evolution* 5:227-238.

Buikstra JE, Ubelaker DH. 1994. *Standards for data collection from human skeletal remains: Proceedings of a seminar at the Field Museum of Natural History*. Fayetteville: Arkansas Archeological Survey Press.

Mays SA. 1998. *The archaeology of human bones*. London: Routledge.

Meindl RS, Lovejoy CO. 1989. Age changes in the pelvis: Implications for paleodemography. Isçan MY, editor. *Age markers in the human skeleton*. Springfield, Illinois: Charles C. Thomas. p 137-168.

Phenice TW. 1969. A newly developed visual method of sexing the os pubis. *American Journal of Physical Anthropology* 30:297-302.

Raxter MH, Auerbach BM, Ruff CB. 2006. Revision of the Fully technique for estimating statures. *American Journal of Physical Anthropology* 130:374-384.

Schwartz JH. 1995. *Skeleton keys: An introduction to human skeletal morphology, development, and analysis*. New York: Oxford University Press.

White TD, Folkens PA. 2000. *Human osteology*. San Diego: Academic Press, Inc.

### Disclaimers:

This report is meant only as a teaching tool for introductory level students of the anatomical, anthropology, or forensic sciences who may be using this specimen to learn about human osteology. Evaluation of skeletal material is best done with original specimens. My evaluation was based solely upon studies of a Bone Clones® replica. My opinions are based solely upon the material presented to me. This is somewhat artificial as in real forensic or archaeological investigations, additional studies would be undertaken prior to the formulation of diagnoses and the production of a report. These studies might include plain film radiography, computed tomography (CT) studies, histology, etc. My opinions regarding sex and ancestry are based only upon non-metric analyses.